

## Metastatic Hemangiopericytoma of the Skin Treated with Wide Local Excision and MGN-3

JODI MARKUS, MD,\* ALICIA MILLER, MD,† MEGAN SMITH, MD,‡ AND IDA ORENGO, MD\*

*Jodi Markus, MD, Alicia Miller, MD, Megan Smith, MD, and Ida Orengo, MD, have indicated no significant interest with commercial supporters.*

This case report describes an uncommon tumor treated with an unproven medication found by the patient during an Internet search.

### Case Report

A 68-year-old white male with a history of multiple cutaneous basal and squamous cell carcinomas was found to have a new 0.5 cm red papule located on the right shoulder. On biopsy, the tumor was a circumscribed cellular nodule located in the dermis. The overlying epidermis was mildly acanthotic. The tumor consisted of round to spindle-shaped cells with a moderate degree of pleomorphism. These were tightly packed between thin-walled vascular channels, lined by a single layer of endothelial cells that in areas had a staghorn appearance (Figure 1). The nuclei were vesicular and had prominent nucleoli. There were occasional mitoses,

with a maximum count of 4 per 10 high-power fields. The tumor cells stained strongly positive for vimentin but were negative for cytokeratin, epithelial membrane antigen, CD68, S-100 protein, and myoglobin. Actin antibodies stained the smooth muscle present around an occasional vessel, and CD34 stained the endothelium (Figure 2). These results are consistent with a diagnosis of hemangiopericytoma.

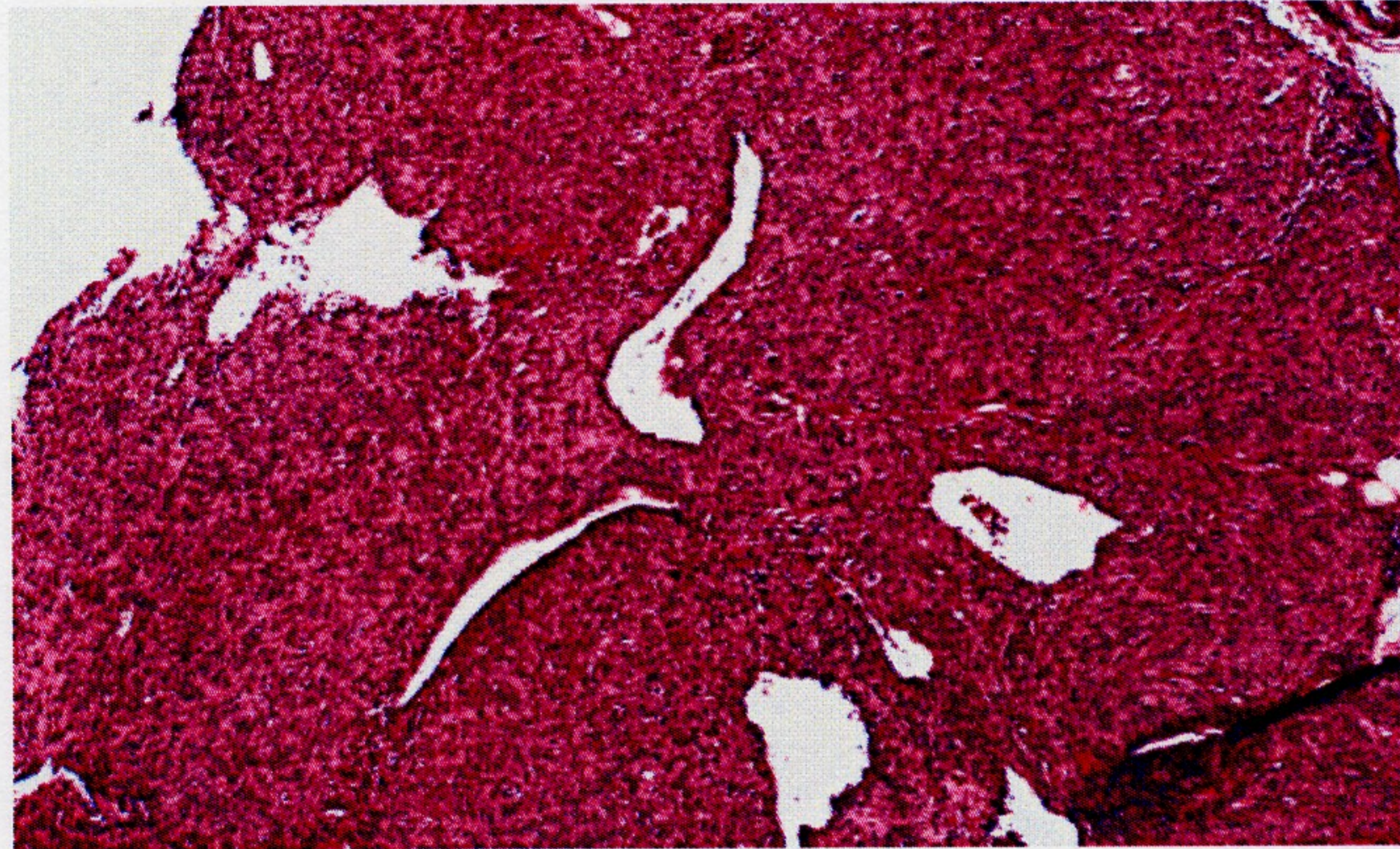
The lesion was removed by wide local excision. Radiologic studies led to the discovery of multiple pulmonary nodules. A hilar lymph node biopsy confirmed the presence of metastatic hemangiopericytoma. He refused further surgical, chemical, or radiation therapies and began taking MGN-3, a biologic response modifier he discovered on the Internet. The lung masses steadily decreased in size by serial imaging, and at the time of this report

submission (34 months after the initiation of therapy), the tumor was undetectable by computed tomography.

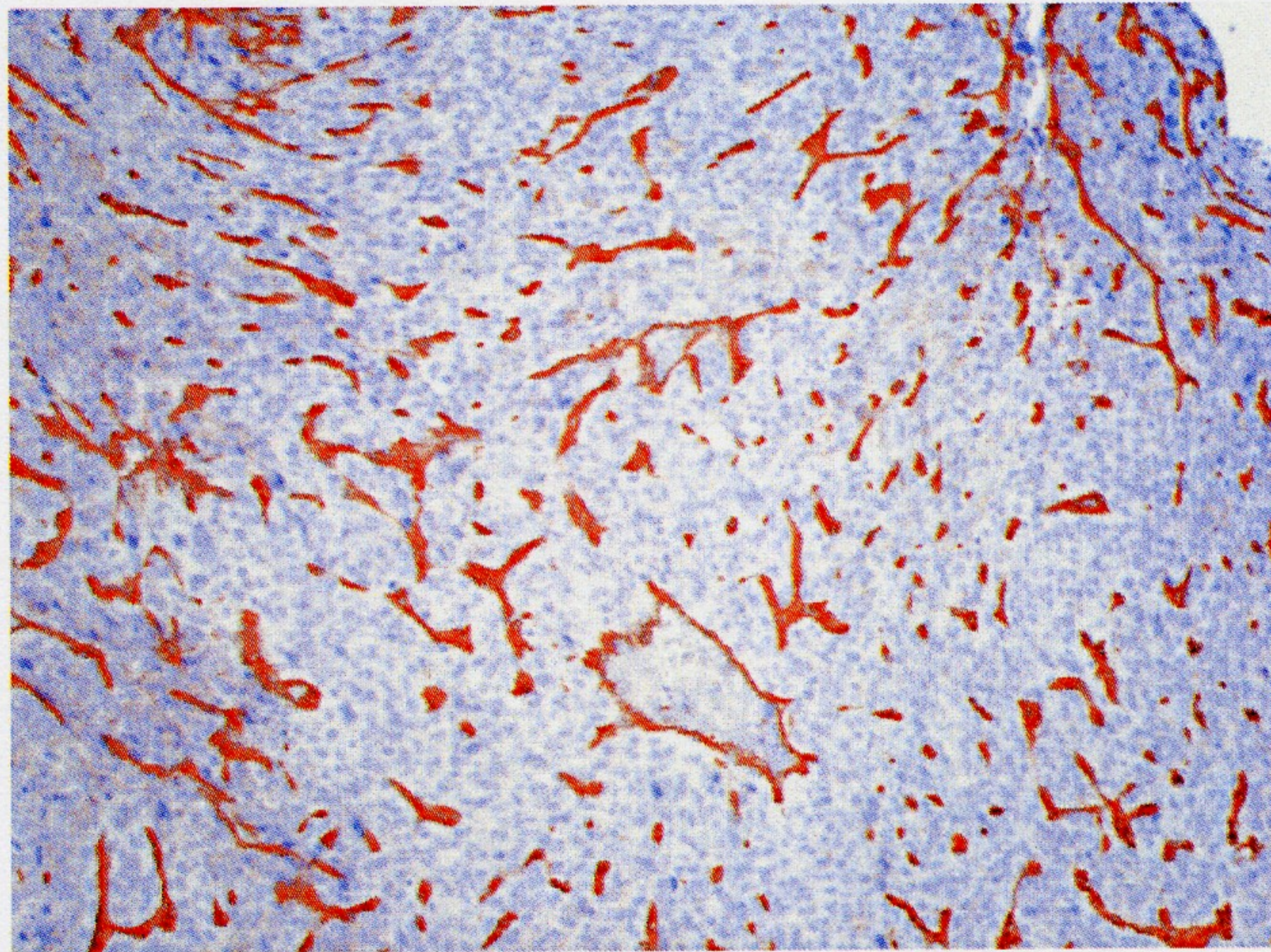
Hemangiopericytoma is an uncommon mesenchymal neoplasm that usually arises in the deep soft tissue of the lower extremities, pelvic fossa, or retroperitoneum.<sup>1</sup> On gross examination, most lesions are solitary, well-circumscribed tumors with a solid, homogeneous appearance of varying color interrupted by a few dilated vascular spaces. Focal areas of hemorrhage, necrosis, or cystic degeneration may be seen.

Since 1942, when Stout and Murray first described the tumor, over 600 cases have been reported.<sup>2</sup> The occurrence of hemangiopericytoma in the skin has been reported in less than 20 cases in the English literature. In many of the cases, the tumor

\*Department of Dermatology and Department of †Dermatopathology, Baylor College of Medicine, Houston, Texas; ‡Department of Dermatology, Mayo Clinic, Jacksonville, Florida



**Figure 1.** A lobulated neoplasm composed of cytologically uniform small, basophilic spindle cells with an oval nucleus and ill-defined cytoplasm. The cells are arranged around numerous thin-walled "staghorn-shaped" vessels (hematoxylin-eosin stain;  $\times 50$  original magnification).



**Figure 2.** Immunohistochemical stain for CD34 (QB-End) highlights the delicate blood vessels. The tumor cells are negative ( $\times 200$  original magnification).

likely originated in the subcutaneous tissue and invaded the dermis. Wide local excision is the treatment of choice with or without adjuvant radiotherapy.<sup>3</sup> The prognosis for patients with hemangiopericytoma is variable and depends largely on the size and location of the tumor and its clinical behavior. To date, no definitive histologic criteria for tumor prognosis have been established. Findings of increased

cellular density, cytologic pleomorphism, focal calcification, hemorrhage, necrosis, and greater than 4 mitoses per 10 high-power fields suggest metastatic potential.<sup>4,5</sup> The total recurrence rate (both local and distant) is reported as 50.5% for musculoskeletal tumors, 41% for intra-abdominal tumors, and 80% for central nervous system tumors.<sup>6</sup> The follow-up intervals for cases of cutaneous heman-

giopericytoma in the literature have not been sufficient to gauge recurrence. Metastatic tumors appear a mean of 8 years following initial therapy and have been reported to occur up to 16 years later.<sup>7</sup> Local tumor recurrence has been reported up to 26 years after initial resection.<sup>8</sup>

MGN-3 is an arabinoxylane derived from rice bran that has been enzymatically modified by an extract of the mushroom *Hyphomycetes mycelia*. In vivo murine studies have reported increased natural killer cell activity with MGN-3 supplementation.<sup>9</sup> An in vitro investigation revealed increased tumor necrosis factor  $\alpha$  and interferon- $\gamma$  production by peripheral blood lymphocytes treated with MGN-3.<sup>10</sup> In addition, MGN-3 was found to enhance anti-CD95 antibody-induced apoptosis in a human leukemic cell line.<sup>11</sup> This biologic response modifier has been studied in a limited number of patients with human immunodeficiency virus (HIV) disease or cancer, with improvement in natural killer cell function and disease activity over time.<sup>12,13</sup> Further studies are needed, however, to ascertain the therapeutic benefits of this relatively novel compound.

It is not uncommon for patients to search the Internet for unconventional treatment options. This patient researched and ordered the medication via the Internet and self-prescribed and self-

monitored his therapy. Although allopathic medicine cannot promote the use of unproven therapies, it is important for physicians to recognize the use of these treatments by their patients.

## References

1. Enzinger FM, Smith BH. Hemangiopericytoma. An analysis of 106 cases. *Hum Pathol* 1976;7:61-82.
2. Stout AP, Murray MR. Hemangiopericytoma. A vascular tumor featuring Zimmermann's pericytes. *Ann Surg* 1942;116:26-33.
3. Pandey M, Kothari KC, Patel DD. Hemangiopericytoma: current status, diagnosis and management. *Eur J Surg Oncol* 1997;23:282-5.
4. Nappi O, Ritter JH, Pettinato G, Wick MR. Hemangiopericytoma: histopathological pattern or clinicopathologic entity? *Semin Diagn Pathol* 1995;12:221-32.
5. Enzinger FM, Weiss SW. Perivascular tumors. In: Weiss SW, Goldblum FR, Enzinger FM. *Soft tissue tumors*. 3rd ed. St Louis: CV Mosby; 1995. p. 713-29.
6. Backwinkel KD, Diddams JA. Hemangiopericytoma. Report of a case and comprehensive review of the literature. *Cancer* 1970;25:896-901.
7. McMaster MJ, Soule EH, Ivins JC. Hemangiopericytoma. A clinicopathologic study and long-term followup of 60 patients. *Cancer* 1975;36:2232-44.
8. Craven JP, Quigley TM, Bolen JW, Raker EJ. Current management and clinical outcome of hemangiopericytomas. *Am J Surg* 1992;163:490-3.
9. Ghoneum M, Abedi S. Enhancement of natural killer cell activity of aged mice by modified arabinoxylan rice bran (MGN-3/Biobran). *J Pharm Pharmacol* 2004 Dec;56:1581-8.
10. Ghoneum M, Jewett A. Production of tumor necrosis factor-alpha and interferon-gamma from human peripheral blood lymphocytes by MGN-3, a modified arabinoxylan from rice bran, and its synergy with interleukin-2 in vitro. *Cancer Detect Prev* 2000;24:314-24.
11. Ghoneum M, Gollapudi S. Modified arabinoxylan rice bran (MGN-3/Biobran) sensitizes human T cell leukemia cells to death receptor (CD95)-induced apoptosis. *Cancer Lett* 2003;201:41-9.
12. Ghoneum M. Anti-HIV activity in vitro of MGN-3, an activated arabinoxylan from rice bran. *Biochem Biophys Res Commun* 1998;243:25-9.
13. Ghoneum M, Mantalla G. NK immunomodulatory function in 27 patients by MGN-3, a modified arabinoxylan from rice bran [abstract]. In: 87th Meeting of the American Association for Cancer Research; 1992 April; Washington, DC.

---

Address correspondence and reprint requests to: Ida Orengo, MD, Baylor College of Medicine, One Baylor Plaza, Houston, TX 77030, or e-mail: iorengo@bcm.edu.